

## Histological Changes in the Lungs of Laboratory Mice Treated with Valsartan and Vitamin E

Ferial Rashid Sukkar<sup>1</sup> and Jabbar Abadi Mohammed<sup>2,\*</sup>

<sup>1</sup>University of Kufa Faculty of Education for girls Department of Biology, Iraq.

<sup>2</sup>University of Kufa/ Faculty of Science Department of Biology, Iraq.

Corresponding author: Jabbar Abadi Mohammed (e-mail: [Jabbara.alaridhi@uokufa.edu.iq](mailto:Jabbara.alaridhi@uokufa.edu.iq)).

©2024 the Author(s). This is an open access article distributed under the terms of the Creative Commons Attribution License (<http://creativecommons.org/licenses/by/4.0>)

**Abstract Background:** This study was conducted in the Department of Biology University of Kufa. Objective :It aimed to demonstrate the effect of using valsartan on the histological structure of the lung in albino mice and the possibility of reducing these effects by treating the animals with vitamin E. mice treated with valsartan with ages (7-8) weeks and weights (26-30 g). **Methods:** 24 adult male Albino mice, divided into 4 groups, 6 mice in per group. The Control group which is the first was injected by NACL (0.1 ml) daily for 30 days, subcutaneously. The second group, the vitamin E treatment group, was injected with vitamin E at a dose of (2 mg/kg) daily for 30days, subcutaneously. The third group was injected with valsartan at a dose of (20 mg/kg) for 30 day, subcutaneously. In the fourth group, the animals were injected with vitamin E at a dose of (2 mg/kg) and valsartan with a (20 mg/kg) dose. After ending the experiment, Mice were all sacrificed. **Results:** After that, histological sections of the lungs of the different groups were prepared and the changes in the histological structure were studied using an light microscope. **Conclusion:** The results showed the protective role of vitamin E in maintaining the lung histological structure in mice treated with valsartan compared to the control treatment.

**Key Words** valsartan, vitamin E, histological changes, lung

### 1. Introduction

Lungs are primary organs in the lower respiratory system , located in the chest where they are protected by a rib cage that contains 12 thoracic vertebrae, 12 pairs of ribs, cartilage, and the sternum [1]. The lungs are the parts of the body where gases are exchanged between atmospheric air and blood. The lungs are a cone-shaped organs [2]. It consists two parts, the right and left half. Each lung is divided into deep fissures [3]. The right part consists three lobes, the lower, middle and upper while the left part consists only two, lower and upper [4]. The bronchioles entering the lungs are simplified into the smallest branches of the respiratory tree . The bronchioles pass through the alveolar duct and form groups of sacs that are described as alveoli [5]. The main function of the lung is exchanging oxygen and carbon dioxide. 80% of the tissue of the lung or more for a healthy adult human, consists of Gas Exchange Parenchyma, that consists approximately 3 hundred million alveoli are centrally arranged round the alveolar sacs as well as ducts [6].

Many factors can affect the lung function . Function of the lungs varies according to age, gender, and height. Lung function may also vary based on an individual's ethnic back-

ground. It may also be affected by weight and body mass index. Or environmentally affects [7].

Vitamins are one of the essential micronutrients, fat soluble. Vitamin E which has antioxidant acts in the Detoxification cascade from fat to water soluble toxic radicals [8]. Therefore, this vitamin has an important role in protecting different tissues from Lipid peroxidation. Also ,Vitamin E dose have many tasks that depend on protein and gene modulating effects in inflammation. It also participates in reducing side effects in patients suffering from cancer [9].

Some experimental studies conducted on humans have shown the role of vitamin E in preventing or alleviating damage to some organs, such as the lungs . Other studies have found a relationship between taking dietary vitamin E and improving the functions of the body's organs [10].

One of the antihypertensive medications is the use of valsartan, Which is taken orally It prevents the action of angiotensin II type I Subtype the receptor competitively as well as selectively, This makes it an effective medication for high blood pressure [11], [12]. Experiments also showed that this drug works on: Insulin resistance in chronic renal failure mice [13] . Some studies indicate that it prevents the

accumulation of stem cells [6]. It also reduces tubular toxicity caused by cyclosporin A By regulating Renal Glutathione Peroxidase (GPx) Expression and alteration of mice oxidative stress [14]. Some researchers believe that Valsartan can be an important treatment in patients with impaired renal function [15], [16].

## 2. Material and Methods

The current study included 40 adult male Albino mice, with ages of (7-8) weeks and weights (26-30 g). That It has been divided into four groups, included There were 6 mice in one group. The first group (control group) was injected with NACL (0.1 ml) daily for 30 days, subcutaneously. The second group, the vitamin E treatment group, was injected with vitamin E at a dose of (2 mg/kg) daily for 30days, subcutaneously. The third group was injected with valsartan at a dose of (20 mg/kg) for 30 day, subcutaneously. while the fourth group, the mice were injected with vitamin E of (2 mg/kg) dose and valsartan at a dose of (20 mg/kg).. and after the end of the experiment The animals were placed inside plastic cages that were covered with an iron clip, and bottles filled with water were placed on top of them were elbow. The boxes were covered with sawdust and replaced periodically [17] . The mice were given Natural granules food and appropriate conditions in laboratory are created, with temperature level between 20-25 °C and 12 hours for both light and darkness as an average. Before this experiment began, all mice were kept for that reason of acclimatization for 2 weeks . During this phase, they were given water and diet [18]. After ending the first experiment all of the mice were sacrificed [19]. They were anesthetized by a mix of 20mg Xylazine and 10mg Ketamine , these mice were placed on a cork dissection plate and fixed by using staples in order to conduct the autopsy process to detect the Vitamin E and Valsartan effects on lung .

## 3. Results

The microscopic examination of the lung in animals that were injected with the drug valsartan for 30 days showed the presence of inflammation and hypertrophy in the lung cells and the presence of fibrosis in the walls of the alveolar sacs, in addition to the occurrence of cell degeneration (Figure 1).

while examining the mice lungs treated with vitamin using microscope , the control treatments and the group treated with the vitamin and antibiotics showed that there were no clear histological changes (Figure 2), as no changes were observed in the histological structure of the lungs of the vitamin E treated group . Likewise, there were no clear pathological changes in the vitamin E and then with valsartan treated group (Figure 3 and 4).

## 4. Discussion

Examining the histological sections of the mice organs treated with vitamin after a period of 1 month using microscope appeared regular histological structure of the lungs in the control group and no exist to any histopathological changes.

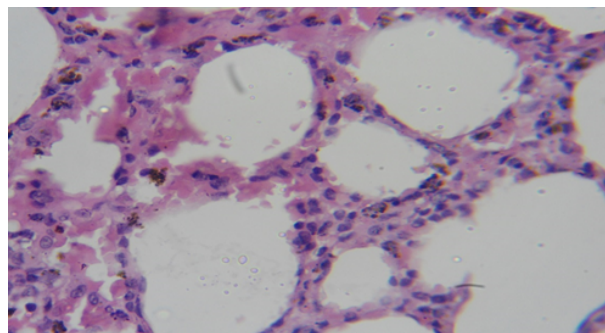


Figure 1: Histological section of the Lung of albino mice treated with normal physiological saline solution shows the normal structure of The alveoli and bronchioles are normal, there is no histological change, hematoxylin-eosin 400x

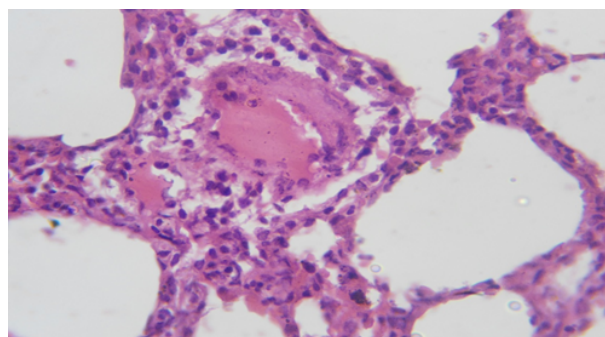


Figure 2: Histological section of the Lung of albino mice treated with valsartan notes the presence of histological changes such as The presence of fibrosis in the walls of the alveoli and blood congestion inside the alveolar sac, hematoxylin-eosin 400x

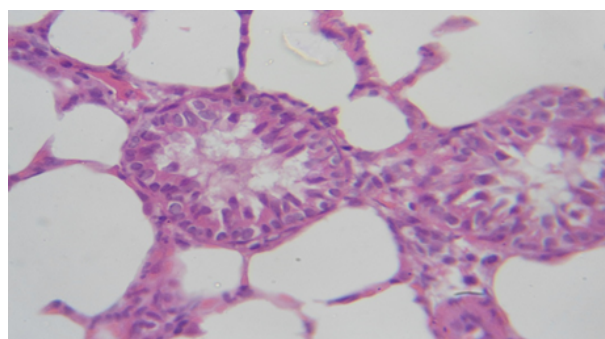


Figure 3: Histological section of the Lung of albino mice treated with Vitamin E and valsartan shows the normal structure of The alveoli and bronchioles are normal, there is no histological change, hematoxylin-eosin 400x

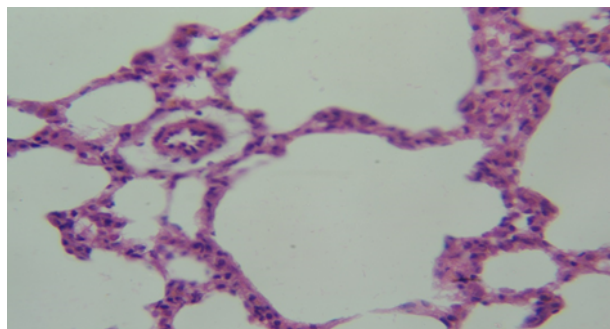


Figure 4: Histological section of the Lung of albino mice treated with Vitamin E and valsartan shows the normal structure of The alveoli and bronchioles are normal, there is no histological change, hematoxylin-eosin 400x

The group treated with vitamin also didn't note any harmful effects. This result is consistent with [20], [21] and is also consistent with what was stated therein [22], who showed that there wasn't any harmful effect of the vitamin on lung functions in animals, this is evidence that vitamin protects the generation of free radicals [23], [24].

This study showed same results with the study [25], in which there wasn't any side effects of vitamin on lung tissue due to the materials it contains that do not stimulate the appearance of oxidative stress or the free radicals generation, nor do they have any effect on tissues that could be toxic. Results of current study also correspond with [26], as the same result appeared in the treated groups in the previous study [27].

Thus vitamins seems to be effective in controlling lung injury in drug-caused by pulmonary toxicity. Valsartan is an effective agent in treating high blood pressure but like any other medications [28].

It has significant harmful effects on various organs of the body, including the lungs [29]. Valsartan sometimes accumulates in the body's organs, including the lungs It causes severity Lung damage. Mechanisms through which valsartan causes pulmonary toxicity are not completely clear. However, many previous reports proved it. Free radicals and Reactive oxygen species are significant Factors contributing to induced pulmonary toxicity [30], [31]. This study has confirmed that VAL treatment It leads to an increase in lung tissue injury. So, Vitamin E has effects of protection on valsartan caused by pulmonary toxicity. Some studies have shown that NO has a role in maintaining normal levels For kidney functions [32], [33]. But within certain limits and not excessive NO formation. Because it becomes harmful and performs a considerable role in tissue damage which cause oxidative stress and tissue damage [34], [35]. The current study showed that lung tissue damage was evident when treated with valsartan, but treatment with vitamin E significantly reduced it. These effects [36], therefore, vitamin E is preferred while using valsartan treatment. It may provide protection against toxicity in the body's cells and organs [37].

### Conflict of interest

The authors declare no conflict of interests. All authors read and approved final version of the paper.

### Authors Contribution

All authors contributed equally in this paper.

### References

- [1] Zaahkhouk, S., Helal, E., Abd-Rabo, T., & Rashed, S. (2000). Carbamate toxicity and protective effect of vitamin A and vitamin E on some biochemical aspects of male albino rats. *The Egyptian Journal of Hospital Medicine*, 1(1), 60-77.
- [2] Abner, E. L., Schmitt, F. A., Mendiondo, M. S., Marcum, J. L., & Kryscio, R. J. (2011). Vitamin E and all-cause mortality: A meta-analysis. *Current Aging Science*, 4, 158-170.
- [3] Galli, F., Bonomini, M., Bartolini, D., Zatini, L., Reboldi, G., Marcantonini, G., ... & Di Pietro, N. (2022). Vitamin E (alpha-tocopherol) metabolism and nutrition in chronic kidney disease. *Antioxidants*, 11(5), 989.
- [4] Kaur, J., Singla, S., & Kumar, N. (2014). In vivo studies on the protective effect of propolis on valsartan-induced toxicity in liver of male rats. *Toxicology International*, 21, 191-195.
- [5] Wang, Y., Wei, R. B., Yang, Y., Su, T. Y., Huang, M. J., Li, P., & Chen, X. M. (2018). Valsartan alleviates insulin resistance in skeletal muscle of chronic renal failure rats. *Medical Science Monitor: International Journal of Experimental and Clinical Research*, 24, 2413.
- [6] Wu, K., Zhou, T., Sun, G., Wang, W., Zhang, Y., Zhang, Y., ... & Chen, N. (2006). Valsartan inhibited the accumulation of dendritic cells in rat fibrotic renal tissue. *Cell Mol Immunol*, 3(3), 213-20.
- [7] Raeisi, S., Ghorbanihaghjo, A., Argani, H., Dastmalchi, S., Ghasemi, B., Ghazizadeh, T., ... & Vatankeh, A. M. (2016). The effects of valsartan on renal glutathione peroxidase expression in alleviation of cyclosporine nephrotoxicity in rats. *BiolImpacts: BI*, 6(3), 119-124.
- [8] Al-Muhana, W. H. Y., & Alaridhi, J. A. M. (2023). Studying protective role of nano-extract of fruits of *Cardi Myxa* plant against effects of indomethacin drug on kidneys of male white rats. *Journal of Chemical Health Risks*, 13(4), 158-165.
- [9] Bhatti, F. R., Mehmood, A., Wajid, N., Rauf, M., Khan, S., & Riazuddin, S. (2013). Vitamin E protects chondrocytes against hydrogen peroxide-induced oxidative stress in vitro. *Inflammation Research*, 62, 781-789.
- [10] Hathcock, J. N., Azzi, A., Blumberg, J., Bray, T., Dickinson, A., Frei, B., ... & Traber, M. G. (2005). Vitamins E and C are safe across a broad range of intakes 1, 2. *The American Journal of Clinical Nutrition*, 81(4), 736-745.
- [11] Single, P. K., Deally, C. M. R., & Weinberg, L. E. (1999). Subcellular effect of valsartan. *Journal of Molecular and Cellular Cardiology*, 19(8), 817-828.
- [12] Pieniazek, A., Czepas, J., Piasecka-Zelga, J., Gwozdziński, K., & Koceva-Chyla, A. (2013). Oxidative stress induced in rat liver by anticancer drugs valsartan, paclitaxel, and docetaxel. *Advances in Medical Sciences*, 58, 104-111.
- [13] Hirahatake, K. M., Jacobs, D. R., Gross, M. D., Bibbins-Domingo, K. B., Shlipak, M. G., Mattix-Kramer, H., & Odegaard, A. O. (2019). The association of serum carotenoids, tocopherols, and ascorbic acid with rapid kidney function decline: the Coronary Artery Risk Development in Young Adults (CARDIA) study. *Journal of Renal Nutrition*, 29(1), 65-73.
- [14] Musawi, B. A. K., Salih, S., Alaridhi, J., & Alyasserli, Z. A. A. (2021). The effects of biotechnology virtual labs approach for enhancing the understanding of 1st-year university students. *Palestinian International Conference on Information and Communication Technology, PICICT 2021*, 175-179.
- [15] Khatami, P. G., Soleimani, A., Sharifi, N., Aghadavod, E., & Asemi, Z. (2016). The effects of high-dose vitamin E supplementation on biomarkers of kidney injury, inflammation, and oxidative stress in patients with diabetic nephropathy: A randomized, double-blind, placebo-controlled trial. *Journal of Clinical Lipidology*, 10, 922-929.
- [16] Hagar, H. H. (2004). The protective effect of taurine against cyclosporine A-induced oxidative stress and hepatotoxicity in rats. *Toxicology Letters*, 151, 335-343.
- [17] Ayla, S., Seckin, I., & Oktem, G. (2011). Valsartan-induced nephrotoxicity: Protective effect of nicotinamide. *International Journal of Cell Biology*, 1100-1155.

- [18] Jansen, E., Viezeleiene, D., Beekhof, P., Gremmer, E., & Ivanov, L. (2018). Effects of higher doses of vitamin E on toxicity and inflammation. *European Journal of Nutrition and Food Safety*, 8, 47–58.
- [19] Kaur, J., Singla, S., & Kumar, N. (2014). In vivo studies on the protective effect of propolis on valsartan-induced toxicity in liver of male rats. *Toxicology International*, 21, 191–195.
- [20] Zhao, X., Zhang, J., Tong, N., Chen, Y., & Luo, Y. (2012). Protective effects of berberine on valsartan-induced hepatotoxicity in mice. *Biological and Pharmaceutical Bulletin*, 35, 796–800.
- [21] Alzoubi, K. H., Khabour, O. F., Salah, H. A., & Hasan, Z. (2013). Vitamin E prevents high-fat high-carbohydrates diet-induced memory impairment: the role of oxidative stress. *Physiology & behavior*, 119, 72–78.
- [22] Abar, E. S., & Alaridhi, J. A. (2019). Study of the effect of aqueous extract of (ginger) *Zingiber officinale* Rosco on the histological structure of the prostate gland of white male rabbits (*Oryctolagus cuniculus*). *Plant Archives*, 19, 293–298.
- [23] Jeon, Y. H. (2013). Vitamin E, an antioxidant, as a possible therapeutic agent for treating pain. *Korean Journal of Pain*, 3, 314–315.
- [24] Saad, S. Y., Najja, T. A., & Alrikabi, A. C. (2001). The preventive role of deferoxamine against acute valsartan-induced cardiac, renal, and hepatic toxicity in rats. *Pharmacological Research*, 43, 211–218.
- [25] Mushattat, S. J., & Alaridi, J. A. (2020). Histological changes in the placenta and some physiological effects for aborted women infected with *Toxoplasma gondii*. *Annals of Biology*, 36(1), 22–25.
- [26] Jeon, Y. H. (2013). Vitamin E, an antioxidant, as a possible therapeutic agent for treating pain. *Korean Journal of Pain*, 3, 314–315.
- [27] Llesuy, S. F., Milei, J., Molina, H., Boveris, A., & Milei, S. (1985). Comparison of lipid peroxidation and myocardial damage induced by adriamycin and 4'-epiadriamycin in mice. *Tumori*, 71, 241–249.
- [28] Mushattat, S. J., & Alaridi, J. A. (2018). Effect of addition of the extract of *Nigella sativa* on the histological and physiological changes of domestic chickens experimentally infected with *Eimeria maxima*. *Journal of Pharmaceutical Sciences and Research*, 10(8), 1934–1938.
- [29] Niki, E. (2014). Role of vitamin E as a lipid-soluble peroxy radical scavenger: In vitro and in vivo evidence. *Free Radical Biology and Medicine*, 66, 3–12.
- [30] Schemitt, E. G., Colares, J. R., Hartmann, R. M., Morgan-Martins, M. I., Marroni, C. A., Tuñón, M. J., & Marroni, N. P. (2016). Effect of glutamine on oxidative stress and inflammation in a rat model of fulminant hepatic failure. *Nutrition Hospitalaria*, 33, 92.
- [31] Mushattat, S. J., Al-Hadraawy, S. K., & Mohammed, J. A. (2018). Effect of magnetized water on reducing the histological and physiological effects of experimental infection with *Ascaridia galli* in domestic chickens. *Journal of Global Pharma Technology*, 10(1), 97–103.
- [32] Chen, Q., Xue, Y., & Sun, J. (2013). Kupffer cell-mediated hepatic injury induced by silica nanoparticles in vitro and in vivo. *International Journal of Nanomedicine*, 8, 1129–1140.
- [33] Mohammad, J. E., & Hasnawi, N. M. (2018). The effect of ciprofloxacin (CPX) on the histological structure of albino rabbit ovary. *Journal of Global Pharma Technology*, 10(3), 498–508.
- [34] Kale, I., Asif Khan, M., Irfan, Y., & Veerana, G. A. (2012). Hepatoprotective potential of ethanolic and aqueous extracts of flowers of *Sesbania grandiflora* (Linn) induced by CCl<sub>4</sub>. *Asian Pacific Journal of Tropical Biomedicine*, 2, S670–S679.
- [35] Al-Shaybany, T. N., Al-Dujaili, A. N., & Al-Aredhi, A. J. A. (2016). Effect of ethanolic extracts of *Salvadora persica* roots on female albino rats. *Research Journal of Pharmaceutical, Biological and Chemical Sciences*, 7(6), 1115–1125.
- [36] Al Ardhil, J. A. M., & Aziz Alshemkhi, M. A. (2016). The histological structure of the thyroid gland and the relationship between hyperthyroidism and total protein, albumin, globulin, liver enzymes, and some mineral deficiencies. *International Journal of PharmTech Research*, 9(8), 189–196.
- [37] Al-Aamelia, M. H., Al-Qazwinib, Y. M., & Mohammed, J. A. (2020). Histological investigation of the effects of cinnamon extract on the skin of male sheep affected by mange. *Systematic Reviews in Pharmacy*, 11(12), 380–386.